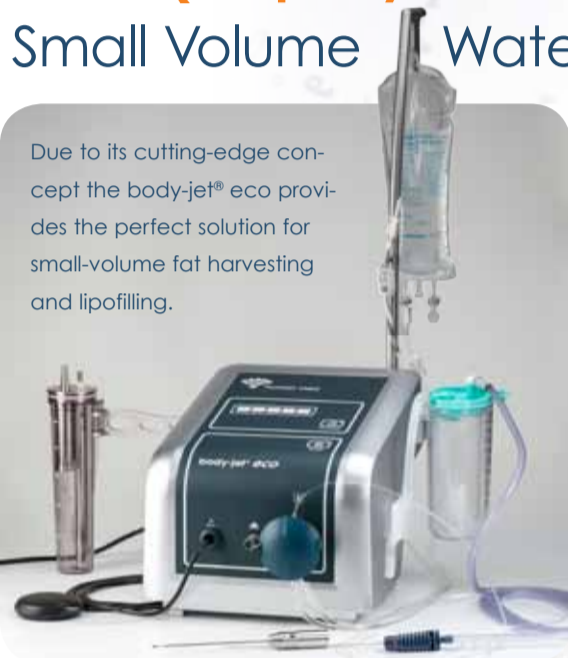


## New Cellgraft® system! All in one!

### body-jet® eco: Harvesting and grafting of fat tissue (adipocytes, SVF, stem cells)

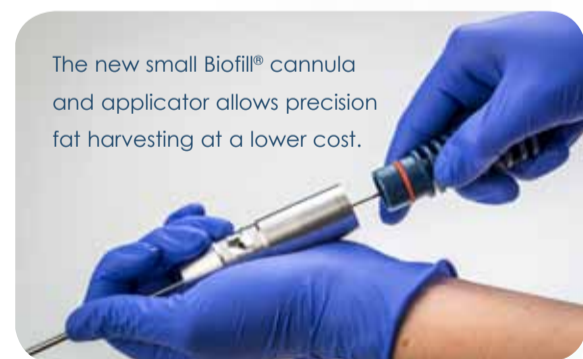#### Small Volume Water-Jet Technology.

Due to its cutting-edge concept the body-jet® eco provides the perfect solution for small-volume fat harvesting and lipofilling.



**ALL IN ONE** – Precision small-volume fat harvesting & lipofilling from local anesthesia to infiltration, fat tissue harvesting, washing, concentration and reinjection:

- 1 compact design - optimized for 20-150 ml fat
- 2 special Biofill® cannula & applicator
- 3 proven high fat tissue viability
- 4 gentle and comfortable procedure
- 5 reproducible and predictable results
- 6 sterile, closed loop system – no centrifugation
- 7 time and cost saving



The new small Biofill® cannula and applicator allows precision fat harvesting at a lower cost.

#### For precise working in sensitive areas!

The innovative body-jet® eco has been designed for the precise and gentle removal of small fat tissue volumes that may be used for subsequent autologous fat transfer. A pulsating water-jet combined

with a tissue-sparing, defined vacuum allows harvesting intact and highly viable fat cells from the subcutaneous fat tissue in a gentle way.

The gentle water-jet technology helps to avoid side effects that may develop in the donor area as a result of a “dry”, manual liposuction, as well as damages to the fat cells often resulting from a too-high syringe vacuum and shear forces.

Harvesting autologous fat with the body-jet® eco saves time and money. This effect becomes significant in the case of small fat tissue volumes from 20 cc.

The fat tissue harvested and collected in a sterile, closed system (body-jet®eco and FillerCollector®) is highly viable, finely dispersed and excellently suited for immediate re-injection due to the optimum lobular size of approx. 0.9 mm. A further treatment of the aspirated tissue such as filtration or centrifugation is not necessary.

Compared to other methods, the results of water-jet assisted liposuction & lipofilling are predictable, as proven by a multitude of published clinical studies. When extracting fat cells the subcutaneous fat tissue, blood, lymph vessels and nerves are spared. The very high fat cell viability of approximately 90 % allows that up to 87 % of the grafted tissue volume is preserved and adheres to the recipient area. The success of the treatment is very well predictable according to numerous clinical studies.

#### Fat harvesting and lipofilling for various applications like

- Hand and face lipofilling
- Wrinkle injection
- Body contouring, e.g. of chin and upper arms
- Soft tissue corrections
- Treatment of radiation and burn scars
- Treatment of chronic, non healing wounds
- Optimized for small volume fat grafting and liposuction

The high viability and very fine fat consistency allows working precisely in small body areas avoiding irregularities during grafting.

## Treatment of Joint Osteoarthritis with Lipoaspirate

C. Herold et al.: Autologous Fat Injection for Treatment of Carpometacarpal Joint Osteoarthritis of the Thumb – A Promising Alternative\*

In a recent publication, Herold et al. are presenting first promising results on the treatment of osteoarthritis with lipoaspirate injections:

“We injected adipose tissue into the thumb carpometacarpal joint in a pilot study. Average preoperative pain according to a VAS was 7.4 in action and 3.8

during rest. It was reduced considerably to 2.2 in action and 0 during rest after 1 month and to 2.4 and 0.8, respectively, 3 months after surgery. The reduction of pain in action was statistically significant 1 month after injection ( $p=0.042$ ). Average grip strength was 78 % and pinch grip strength was 74 % in comparison

to the healthy side preoperatively, 89 % and 80 % one month postoperatively and 93 % and 89 %, respectively, 3 months postoperatively. An average DASH score of 58 preoperative was reduced to 36 after 1 month and 33 after 3 months.

The amelioration of hand function was statistically significant ( $p=0.042$  and

$p=0.043$ ). There were no side effects and all patients were satisfied. These preliminary results are promising. Adipose tissue injection seems to be an alternative to consider, especially as it does not exclude classical surgical options in cases of failure.”

# WATER-JET ASSISTED FAT GRAFTING FOR THE FACE

Yves Surlemont, M.D., Clinique Saint Antoine, Chirurgie plastique et esthétique, Rouen, France



new injection cannulas

## Short Guideline for Face Lipofilling

### INTRODUCTION

Autologous fat as a filler has great advantages because it uses the patient's own tissue, it is less expensive, and delivers the required quantity to the desired region, with long lasting results.

### TECHNIQUE

The procedure is carried out,

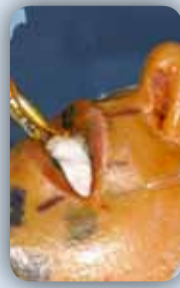- either under local anaesthesia with or without oral pre-medication, depending on the level of anxiety and the reaction to pain,
- or under general anaesthesia. This is also recommended when fat grafting is associated with other procedures.

On the donor site, local anaesthesia is provided by the water-jet. This is more efficient than the usual application of local anaesthesia. It is applied with adrenaline and lidocaine or even general anaesthesia, in order to obtain temporary vasoconstriction, and to limit haematoma. This is done with a 25 gauge needle at the cannula entry point into the skin, then with a cannula (1mm in diameter) after creation of an entry point with an 18 gauge needle.

**Marking:** It always begins with accurate markings and drawings of the face in a sitting position in order to visualize the

effect of gravity.

The harvesting of adipose tissue is done by water-jet assisted lipoaspiration with the **body-jet®eco**, either under local anaesthesia or under general anaesthesia. Sterile closed loop collection, filtering, washing and concentration of the lipoaspirate is done with the **FillerCollector®** which is connected to the **body-jet®eco**. This provides a viable, evenly dispersed fat quantity within a short time (10 to 15 minutes for the first 100 cc of lipoaspirate).



For the face, the 3.5 mm **Biofill®** cannula is used. Due to the water-jet capillary inside the **Biofill®** cannula, the lobular size of the harvested fat cell clusters is 0.7 – 0.9 mm which is the optimum size for the survival of the fat transplant in the recipient tissue. This technique allows simultaneous infiltration and aspiration via the same **Biofill®** cannula. It is preferable that the sampling region should be one that is resistant to weight loss.

**No preparation** of adipose tissue is required apart from decanting. The water phase in the **FillerCollector®** is drained

automatically by the vacuum of the **body-jet®eco**. Thus, the obtained adipose tissue is fluid with a remaining serum content of 20 to 25 %, and can pass through the injection cannula smoothly and without damaging the adipocytes. The lipofilling into the face is more regular and reduces the risk of any lumps.

### Instruments used:

- 1ml syringes,
- **BEAULI®** injection cannulas of 1.4 mm outer diameter/1.0 mm inner diameter, lateral long hole 3.4 mm or tip angular cut 65° (human med AG),
- in special cases, intradermical 25 gauge needles, if possible 23 gauge needles.

The technique is the same as recommended by Sydney Coleman 15 years ago, maximizing regeneration and revascularisation of the fat graft.

- Start by making a tunnel with the injection cannula followed by depositing single adipose tissue particles in the tunnel while retracting the cannula.
- Create multiple separate tunnels in many layers and always deposit single adipose tissue particles in the tunnels while retracting the cannula.
- Join the tunnels.
- Thus, the individual fat particles or micro fat droplets that are "seeded" into

the recipient tissue, will be regenerated and revascularized.

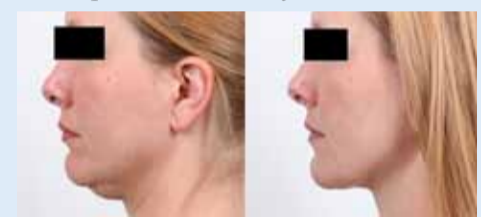### Working in 3 dimensions helps to

- eliminate the risk of having larger adipose tissue particles between the vessels, so as to prevent necrosis of the central area.
- avoid a major rise in intra-tissue pressure within the recipient area, and the compression of the vessels which could lead to ischemia and necrosis, and finally to the loss of the tissue graft.

**Quantity** limits should be respected; grafting of too much volume will lead to a loss of part of the graft. Dressing is done at the end of the surgery with **Steri-strips™** in order to maintain position of the treated areas while ensuring revascularisation of the grafts.

### CONCLUSION

Like all techniques lipofilling to the face has its own rules and limits that must be known and respected, alone or together with other techniques for satisfactory results.



Water-jet assisted facial liposuction & lipotransfer (courtesy J. Ditesheim, [www.empowermd.com](http://www.empowermd.com))

## Water-Jet Breast Augmentation Results from Asia

T.J. Kang M.D., Ph.D. of Yujin Esthetics Clinic (South Korea) reports about his experience with water-jet assisted fat grafting for breast augmentation. He is on the South Korean Board of Plastic Surgery, and his specialty is breast surgeries.



"I got introduced to breast augmentation with autologous fat during the **BEAULI** Workshop in Berlin, Germany, in June 2009. At that time, this method was not recommended in South Korea, therefore it was a kind of "culture shock". However during the **BEAULI** Workshop, I observed the procedures and results carefully and came to the conclusion that this method was not only safe but also efficient.

My method for breast augmentation with fat starts with the use of **body-jet® evo**. The fat is harvested from the thigh or abdomen. After collection and filtering in the **LipoCollector®**, the fat is simultaneously injected into the patient's breast. This procedure is repeated 3 months later, if the patient requests larger augmentations.

Due to the Asian skin type, which is tighter than of western women, most of my patients use the **BRAVA** system for pre-expansion of the breast tissue for about 3-4 weeks before the actual surgery day.

The advantages of using the **body-jet® evo** is simply amazing because my results are more constant and the survival rate of the grafted fat is much higher. There is the factor of time as well as the operations are faster. The risk of infections is much lower because there is no air contact. Also, from my observations and experience, my patients seem to be more comfortable during and after the surgery.

I used this method for approximately 2,400 successful operations during 4 years. About 80 % of my patients are satisfied with their results. For the remaining 20 % I have contingency plans, which are a) repeat the fat grafting procedure, or b) switch to silicone implants.

## COMPOSITE BREAST AUGMENTATION

### INTERVIEW WITH DR. C. A. SALZBERG, NEW YORK, USA

The new concept of breast augmentation using the core projection of implants covered with the natural look and feel of the patient's own fat (Composite) has become popular.

In the following interview, Dr. C. Andrew Salzberg, M.D., Associate Professor in the Division of Plastic Surgery, New York Medical College, and Attending Mount Sinai Medical Center, New York, USA explains the method.

### Dr. Salzberg what do you like about the method of combining implants with autologous fat for breast augmentation?

The ability to alter the shape and contour of the breast with both an implant and subcutaneous fat transfer at the same time allows the surgeon unparalleled capability to refine the beauty of the breast and the ability to place one's own tissue in exactly the needed areas of the breast.

### What is the main advantage of combining implant and autologous fat?

Autologous fat is the natural filler. It allows for consistent and persistent correction of breast deformities and volume deficiencies.

### What method do you apply for fat harvesting and lipofilling?

I use water-jet assisted liposuction and lipofilling.

### What do you like about the water-jet method?

I enjoy the ease of use and effectiveness of the **body-jet®** and the **LipoCollector®**. The system is contained from suction to collection, filtering and up to reinjection. I also appreciate the preservation of the fat tissue by the water-jet technology and the ease of reinjection. With combining implants and water-jet assisted fat grafting, I get reliable results in a one stage procedure.

### Can you give us some key technical points of the procedure?

I do a subpectoral implant placement followed by subcutaneous tissue transfer only into retro mammary and subcutaneous spaces. After the operation I recommend only light compression or none at all for immediate tissue healing.

### What are your main applications of fat grafting with body-jet®?

I mainly use the **body-jet®** for liposuction, fat grafting, breast augmentation, buttock augmentation and correction of soft tissue defects, lipofilling in the face and hands, and for the treatment of burn scars and chronic lower extremity wounds.



## Water-jet assisted dissection during face lift procedures

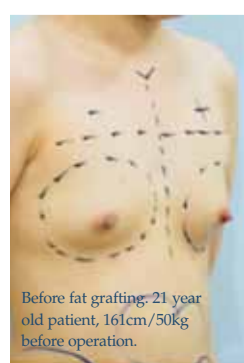
Dr. Thomas Tork, Ahlen, Germany: 10 years of Experience with **Aqualift** – how does it make the Life of Surgeon and Patient easier?\*

Hydrodissection is the key principle of a facelift concept called the **Aqualift**.

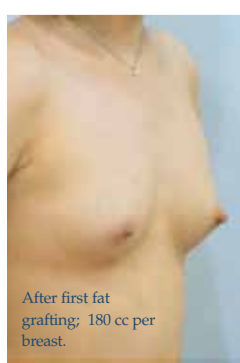"With **Aqualift** the water-jet technology combines minimal impact and collateral damage with powerful dissection. For example, using the mobilization force of the water-jet, the mandibular ligaments, that have to be dissected for a natural reposition of the facial structures, can be addressed with minimal risk of nerve irritation or damage. With this technique there is significantly less bleeding in comparison to the conventional technique of translumination. Besides the advantages of the tissue selective characteristics of the water-jet, the dissection takes place considerably faster thus reducing the overall procedure time.

Another advantage for both the patient and the surgeon is, that the procedure does not require drainage of the operation site by redon drainages and can be performed as an outpatient procedure.

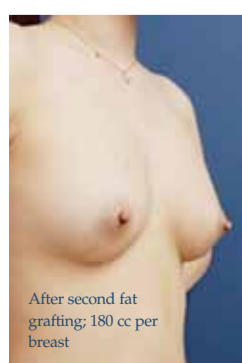
Compliance and follow up are easier, when the patients do not suffer from severe bruising and swelling. Even for smokers there is minimized danger of healing complications because of less trauma due to the gentle water-jet dissection." \* Presentation Las Vegas Cosmetic Surgery & Aesthetic Dermatology Congress, June 2014



Before fat grafting; 21 year old patient, 161cm/50kg before operation.



After first fat grafting; 180 cc per breast.



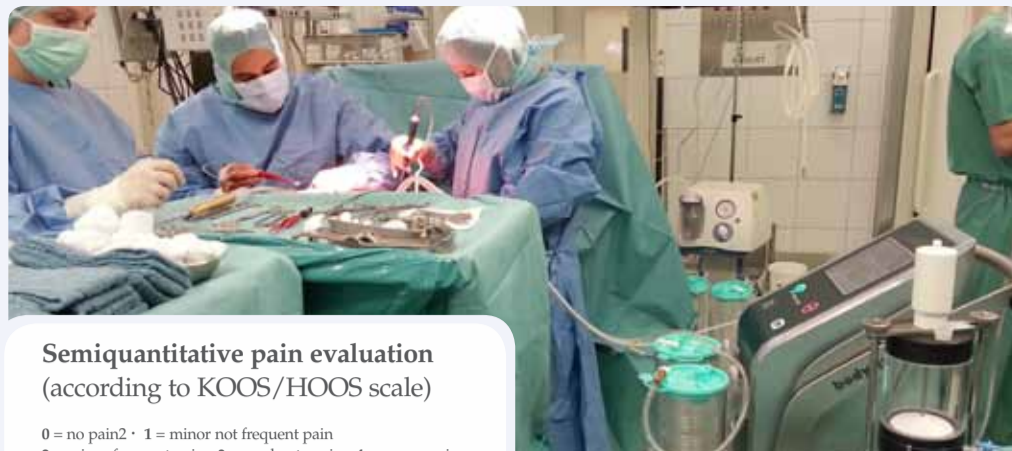After second fat grafting; 180 cc per breast

# Successful treatment of Osteoarthritis with Stromal Vascular Fraction and Adipose Stem Cells

Michalek J. et al.: Stem Cell Therapy of Osteoarthritis Using Stromal Vascular Fraction Cells\*

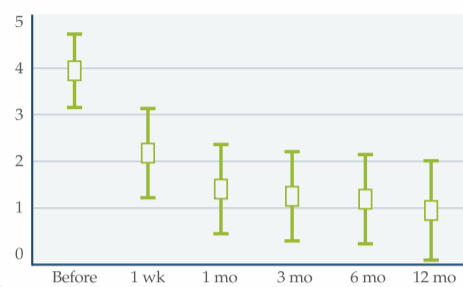
The authors "performed a pilot study using a novel stem cell therapy approach that was performed during one surgical procedure. It relies on abdominal lipoaspiration and processing of connective tissue to stromal vascular fraction (SVF) cells that typically contain relatively large amounts of mesenchymal stromal and stem cells. SVF cells are injected immediately to the target joint or to the connective tissue of the target joint. Since 2011, total of 1128 patients have been treated with SVF injections into 1 - 4 joints (knees and hips) per patient. A total num-

ber of 1769 joints were treated. Clinical scale evaluation including pain, non-steroid analgesic usage, limping, extent of joint movement and stiffness was used as measurement of the clinical effect. All patients were diagnosed with stage II-IV osteoarthritis using clinical examination and X-ray, in some cases MRI was also performed to monitor the changes before and after stem cell therapy. Results: After 12 months from SVF therapy, and clinical scale evaluation, 81% of patients had at least 50% improvement of clinical disorders, and 47% of patients had at least 75% clinical improvement, respectively. Within 1-2 weeks from SVF therapy



## Semiquantitative pain evaluation (according to KOOS/HOOS scale)

0 = no pain · 1 = minor not frequent pain  
2 = minor frequent pain · 3 = moderate pain · 4 = severe pain  
5 = unbearable pain requiring everyday use of painkillers



72% of patients were off the non-steroid analgesics and most of them remained such for at least 12 months. No serious side effects, infection or cancer was associated with SVF cell therapy."

\*Stem Cell Therapy of Osteoarthritis Using Stromal Vascular Fraction Cells - Proceeding of the STEMSO Conference, CellR4 2014; 2 (1): e778

# High adipose stem cell numbers and viability in adipose tissue harvested by water-jet assisted liposuction

Dr. rer. nat. et med. habil. Kirsten Peters, Rostock University Medical Center, Department of Cell Biology: Characterization of adipose-derived stem cells isolated from water-jet harvested fat

In a study of the Department of Cell Biology of the Rostock University Medical Center the content and viability of adipose stem cells in adipose tissue harvested by water-jet assisted (WAL) liposuction (body-jet® system), combined with the LipoCollector® has been investigated.

## The study concludes that

- cell population isolated from WAL-isolated adipose tissue contains a large number of highly viable adMSC (15% of the processed lipoaspirate/PLA are plastic adherent and CD34-positive);
- adMSC from WAL-isolated adipose tissue possess a specific mesenchymal differentiation capacity (tested were adipogenic and osteogenic differentiation).

The total cell number (SVF) after flow cytometry was 440,000 cells per g lipoaspirate,

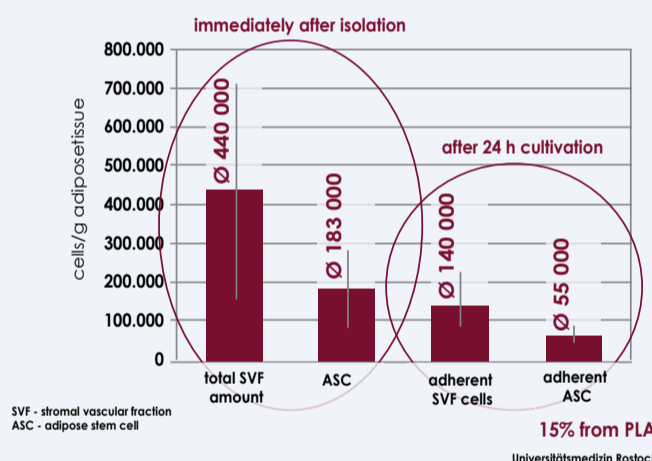
and the number of CD34+ (mesenchymal) cells was 183,000 cells per g lipoaspirate. After 24h incubation the total number of plastic adherent cells (SVF) was 140,000 cells per g lipoaspirate, and the number of plastic adherent CD34+ (mesenchymal) cells was 65,000 cells per g lipoaspirate.

## Patients and Methods:

- Female patients age: 45.5 y (±12 y), n=6.
- Adipose tissue from female abdomen, fundament and thigh.
- Tumescence solution containing epinephrine, sodium-bicarbonate and lidocaine in 0.9% saline.
- Suction vacuum was 0.5 bar, 3.8 mm infiltration and aspiration cannula.
- Tissue digestion with collagenase/neutral proteases (30 min, 37°C), washing and centrifugation.
- Analysis of viability by flow cytometry.

- CD34 surface marker (analysis and positive selection).
- Standard cultivation conditions.
- Cellular differentiation was induced by standard supplements (osteogenic: dexamethasone, ascorbic acid, glycerophosphate; adipogenic: dexamethasone, IBMX, indometacin, insulin).
- Analysis of osteogenic and adipogenic differentiation capacity.

## Adipose stem cell numbers



# Autologous fat grafting (lipofilling) allows wound healing in chronic, previously non-healing ulcers in diabetic patients

Dr. Tilman Stasch et al, Aachen, Germany: AUTOLOGOUS FAT GRAFTING (LIPOFILLING) FOR CHRONIC ULCERATION ON THE DIABETIC FOOT IMPROVES WOUND HEALING\*

During the 2013 ISPRES congress, T. Stasch presented a case series on the healing progress of chronic, non-healing lower-limb wounds in diabetic patients following peri-lesional autologous fat grafting.

"The study included 16 diabetic patients (11 men and 5 women) with deep, non-healing chronic foot ulcerations that were previously unsuccessfully treated with traditional methods for a mean of 6 months (range, 2-33). In all patients, peripheral vascular perfusion had been optimized if possible. The ulcers were debrided and lipoaspirate was injected peri-lesionally."

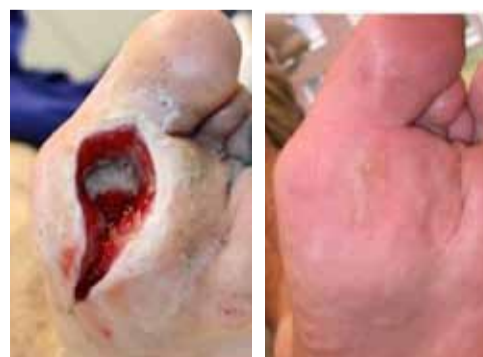**Methods:** "The non-processed lipoaspirate (mean 7.7 +/- 3.9 ml) was then transferred

into the wounds using a closed system, with peri-lesional infiltration into the edges and base of the chronic wounds. The wound was then covered with a PVA foam and negative pressure applied (VAC-System) for 5 days. Thereafter the wounds were regularly assessed and measured and covered with Suprasorb H® dressings until complete healing. Healing was defined as complete reepithelialisation of the wound. Wound sizes were measured and analysed using digital photography."

**Results:** "Wound size after debridement averaged 4.8 +/- 3.6 cm<sup>2</sup>. 13/16 wounds (81%) of wounds healed completely within a mean of 10 weeks. In 2 patients with particularly deep ulcers, another session of lipofilling lead to complete wound healing after another 4 weeks. All patients were followed up for at least 4 months after wound healing which showed stable tissues in all."

**Discussion:** "Chronic ulcers on the lower

diabetic limb pose a particularly challenging situation with a high morbidity for the patient often associated with recurrent surgical debridements and eventually amputations in a compromised vascularized environment. This study shows the enormous effects of autologous fatgrafting on wound healing as a relatively easy to perform and well tolerated procedure. " \*Abstract 2nd ISPRES, Berlin 2013



1. Chronic ulcer, pre-op  
2. Healed foot after 8 weeks, one lipofilling session

# Lymph Sparing Liposuction for Lipoedema - American-European Expert-Meeting

Catherine Seo, Professor of Management at Cambridge College, Boston USA, and advocate for lipoedema patients (see www.lipoedema-simplified.org) convened an International Gathering of American and European experts to meet on developing a standard of care for the treatment of lipoedema in Frankfurt, Germany on 16 March 2014.

After a misdiagnosis in 2011 that resulted in life-changing serious complications, Catherine learned that she has lipoedema and in fact has had it for many years since early puberty. She unsuccessfully sought answers from many specialists in the US discovering that "knowledge about lipoedema is almost non-existent in the US at this time." However, there are 17 million women with unrecognized and misdiagnosed lipoedema in the US alone, with over 3 million in both Germany and the UK. In her search for experts she went to Europe and found, interviewed and filmed for a documentary about lipoedema, the most experienced plastic surgeons and their operation procedures in Germany, The Netherlands and Great Britain.

Among those she visited German plastic surgeons Dr. Josef Stutz\* and Dr. Christian Falk-Heck who have been treating lipoedema patients with gentle water-jet assisted liposuction with very good results for many years. She successfully underwent WAL surgery in Schwarzenbach am Wald, Germany with Dr. Stutz the week after the gathering, which greatly improved her gait and diminished pain. She is planning to have two additional WAL surgeries later during 2014.

From the USA, Drs. Mark Smith and Joseph Dayan from Mt. Sinai Beth Israel in New York City took part in the meeting. They will start offering medically reconstructive lymph sparing liposuction for lipoedema beginning in the fall of 2014. They are currently working with doctors in Germany to bring this treatment to the USA. One of the highlights of the meeting was the active participation of lipoedema patient support groups from the US, Netherlands, Great Britain and Germany. All participants agreed on the success of the meeting in defining future strategies for the improvement of lipoedema treatment.

\*J. J. Stutz, D. Krahl: Water Jet-Assisted Liposuction for Patients with Lipoedema: Histologic and Immunohistologic Analysis of the Aspirates of 30 Lipoedema Patients. Aesthetic Plast Surg. 2009 Mar;33(2):153-62

## 1. Safe and controlled removal of fat tissue - surgery times reduced by 40%

Taufig, A. Z.: Water-Jet Assisted Liposuction. In: Liposuction - Principles and Practice. Springer 2006; 326-330.

280 patients were treated from October 1999 until March 2003."

**Results:** "The targeted fragmented removal of the fat tissue allows the achievement of the desired result in a controlled and safe way. Surgery times can be reduced by more than 40%. The technique of water-jet liposuction is a safe, gentle and targeted method to remove subcutaneous fat build-ups. It offers a very good way for molding the tissue during the operation.

Drug-related side effects are not to be expected. The method is simple, easily explained to the patient and quickly learned by the surgeon. The postoperative leakage of fluid from the incisions with the tumescent method is largely reduced if not even stopped with the new water-jet method."

## 2. Less pain and side effects - faster recovery

Araco, A., Gravante, M.D., Araco, F., Delogu, D., Cervelli, V.: Comparison of Power Water-Assisted and Traditional Liposuction: A Prospective Randomized Trial of Postoperative Pain. Aesth. Plast. Surg. 31: 259 - 265; 2007.

A prospective randomized trial compared power water-assisted liposuction with the traditional tumescent technique. Patients were randomly assigned to water-assisted or traditional liposuction.

**Results:** "From September 2005 to December 2005, 60 patients were recruited and analyzed. For the study, 28 patients were randomized to traditional liposuction and 32 to power water-assisted liposuction. A significant difference in postoperative pain was observed ( $p < 0.05$ ). After 4 days, 87% of the patients who underwent power water-assisted liposuction were completely pain free, as compared with 3.6% of those treated with traditional liposuction. Furthermore, ecchymosis was significantly less for the patients who underwent power-assisted liposuction ( $p < 0.05$ ).

The study findings demonstrate that water-assisted liposuction is an almost painless procedure that produces less tissue trauma than traditional liposuction."

## 3. Precision body shaping - less pain - less absorption of tumescent solution - local anesthesia

Man, D.; Meyer, H.: Water Jet-Assisted Lipoplasty. Aesthetic Surgery Journal; May/June 2007, 342 - 346.

In total, the authors "have carried out more than 800 treatments since 2001".

**Results:** "Compared with the quantity of tumescent solution used in conventional manual lipoplasty (100%), an average of 20% to 30% was used in preinfiltration". "The length of time tumescent solution remains in the tissue, as well as the resulting absorption times, are all considerably lower for the recommended infiltration solutions compared with all other tumescence-based lipoplasty techniques."

"The average patient satisfaction rate for both the procedure and the final outcome was higher than 94%."

**Conclusions:** "On the basis of our clinical experience administering body-jet WAL with the patient under local anesthesia, we have found that:

1. WAL presents a new and safe method that is suitable for all types of lipoplasty.
2. In almost all cases, WAL facilitates use of preinfiltration of modified tumescent solution to create analgesia that is suitable for the performance of painless or near painless lipoplasty. Therefore lipoplasty with the patient under general anesthesia or sedation that suppresses consciousness is no longer necessary.
3. There is significantly reduced pain-related impairment during and after the procedure compared with standard tumescent technique. Patients recover quickly and return to normal daily activities rapidly.
4. Considerably less intraoperative swelling allows the surgeon to realize the target result with greater precision.
5. Fine shaping of small deposits with precision is also possible."

## 4. Lipoedema - atraumatic liposuction - high fat cell viability

Stutz, J.J.: Water-Jet Assisted Liposuction for Patients with Lipoedema: Histologic and Immunohistologic Analysis of the Aspirates of 30 Lipoedema Patients. Aesthetic Plastic Surgery (2009)33: 153-162.

"The atraumatic, anatomically appropriate procedure of water jet-assisted liposuction available today represents a promising treatment for Lipoedema patients who generally suffer from severe subjective and objective impairment. Liposuction treatment can bring long-term improvement if the operative technique focuses on lymph vessel preservation. Immunohistologic analyses show minimal evidence of lymph vessel structures in lipoaspirates. The histologic analysis of the aspirates documents a relatively specific removal ("apheresis") of primarily intact lipocytes with low vascular amount."

"After water-assisted liposuction with the body-jet®, the lipocytes in the aspirate were shown to be predominantly intact: "In 28 of the 30 investigated lipoaspirates (patients), the lipocytes were found to be predominantly (>70%) intact."

## 5. Breast augmentation - permanent take rate up 87% - MRI controlled

Ueberreiter K et al. BEAULI™ - A New and Easy Method for Large Volume Fat Grafts. Handchir Mikročir Plast Chir 2010; 42:379 - 385.

Ueberreiter et al. present "a new and reliable procedure to collect larger amounts of transplantable fatty tissue. It was evaluated in a prospective clinical study with 85 patients in 2 centres in Germany, the overall number of transplantations amounting to 216 treated breasts. Indications were general lack of breast volume, either genuine or acquired in the course of surgical procedures. The fat was harvested with the BEAULI™ method, which consists in general of the harvest of very small fat particles by means of water-assisted liposuction (body-jet®, human med AG, Germany) and reinjection of the fat after separation from superfluous water by means of the LipoCollector®."

"An MRI of the breasts was taken preop and 6 months postoperatively, the longest follow-up is 30 months. Operation time was (on average) 1.5 h. The volume control of 35 aesthetic patients by means of BrainLab™ Software and MRI could verify a permanent take rate of  $76 \pm 11\%$  of the grafted fat. In aesthetic patients generally 2 (80%) fat-grafting procedures with an average gain in volume of 1 / 2 bra cup size or 100 - 150 ml) per procedure were required. After implant removal, satisfaction was usually reached after only a single procedure, for complete reconstruction after cancer surgery 4 - 5 grafting sessions were necessary. An extension of the skin envelope as well as improvement of existing scars were observed."

## 6. Breast augmentation - fat grafting periglandular 81% versus intrapectoral muscle 65%

C. Herold, K. Ueberreiter, F. Cromme, M. Grimme, P. M. Vogt. Is there a need for intrapectoral injection in autologous fat transplantation to the breast? - An MRI volumetric study. Handchir Mikročir Plast Chir 2011; 43: 119 - 124.

Herold et al. compared the volume of transplanted fat in pectoral muscles and periglandular fat. The fat was analysed by MRI volumetry before and 6 months after autologous fat transplantation in 10 patients" using water-jet assisted liposuction (body-jet®).

**Results:** By comparison of the volumes calculated with MRI volumetry preoperatively and postoperatively, the study "revealed a mean volume persistence of 65% (+13%) within the pectoral muscle and of 81% (+8%) within the periglandular fat". The authors conclude that "in autologous fat transplantation to the breast the periglandular plane is superior to the intramuscular plane in terms of volume persistence".

## 7. WAL fat grafting safety & effectiveness - fat cell viability 90% - infiltration-to-aspiration ratio

G.H. Sasaki: Water-Assisted Liposuction for Body Contouring and Lipoharvesting - Safety and Efficacy in 41 Consecutive Patients. Aesthetic Surgery Journal 2011; 31: 76.

In this study, "forty-one consecutive patients were treated with WAL (Body-Jet; Human Med) for mild-to-moderate body contouring. Patients were given local anesthesia (standardized tumescent solutions) during all three phases of the surgery. During the latter two phases, irrigation of tumescent solution was accompanied simultaneously by suction aspiration. Fat harvesting was accomplished by collecting and separating the aspirated adipose tissue in a sterile container LipoCollector®), without need for washing or centrifugation. Fat grafting by microdroplet technique was performed within two hours of collection. Fat aliquots from five randomly-selected patients were assessed with a trypan blue dye exclusion test within one hour and again six to eight hours after collection."

**Results:** "A total of 37 females and four males underwent WAL in this series; average body mass index (BMI) was 25.5. Among the 41 patients, 166 areas involving twelve anatomic sites were treated. Patients were divided into two groups based on the volume of treatment: Group 1 contained 19 patients with small-volume WAL and Group 2 had 22 cases of moderate-volume WAL. All patients experienced uneventful recovery periods with minimal side effects and no significant complications. Although large volumes of tumescent solution were required during the three phases of the technique, the total volume of infiltration almost equaled the final volume of aspiration. The average infiltration-to-aspiration ratio was 1.1 to 1.0 in all cases over both groups. Lidocaine dosage averaged 10.5mg/kg in Group 1 and 20.0mg/kg in Group 2."

"Trypan blue dye exclusion testing indicated that about 90% of adipocytes expelled the dye after one hour of extraction (meaning 90% cell viability), while an estimated 10% of cells per patient were observed to be free of dye six to eight hours after removal."

The author concludes that the "amount of instilled

tumescent fluid, lidocaine dosage, and aspiration volumes appeared to be safe, with minimal blood loss in small and moderate volume liposuction cases".

## 8. Fat grafting after silicone implant removal due to capsular contracture

K.Ueberreiter, U.Tanzella, F. Cromme et al.: One stage rescue procedure after capsular contracture of breast implants with autologous fat grafts collected by water assisted liposuction ("BEAULI Method"). GMS Interdisciplinary Plastic and Reconstructive Surgery DGPW 2013, Vol. 2, ISSN 2193-8091

In this study on the replacement of breast volume after removal of contracted silicone implants, the authors summarize their results as follows:

"Between January 2008 and October 2012 a total of 64 patients (124 breasts) with capsular fibrosis Baker III to IV were treated with autologous fat grafts collected with the body-jet® by water-assisted liposuction ("BEAULI Method")."

"Magnetic resonance imaging (MRI) of the breasts was performed in 5 patients preoperatively and 6 months postoperatively, a clinical examination and photo documentation of all patients was done on day 1 and after 4 weeks, 12 weeks and 6 months postoperatively. The procedure included implant removal and lipofilling of the subcutaneous and intra-muscular space in a single procedure by means of the BEAULI Method.

The average gross amount of grafted fat was 260 ml. The average drainage time was one day. The shape of the breast changed to a more natural and ptotic form. Negative side effects like oily cysts or infections were not observed. The time of the overall procedure including liposuction was  $70 \pm 15$  min." The authors comment that they "could add a relatively simple and efficient procedure to resolve and improve those cases by autologous fat transfer using water-jet assisted liposuction and the BEAULI Method."

## 9. Total breast reconstruction with WAL in cancer patients

D. Hoppe, K. Ueberreiter, Y. Surlemont, H. Peltoniemi, M. Stabile, S. Kauhanen: Breast reconstruction de novo by water-jet assisted autologous fat grafting - a retrospective study. GMS German Medical Science 2013, Vol. 11, ISSN 1612-3174

This retrospective European multicenter trial included "135 procedures on 28 (35 breasts) postmastectomy patients (mean 52.4 years)."

"All women were treated with the water-jet assisted fat grafting method (BEAULI™) combined with additional procedures (NAC reconstruction, contralateral mastopasty) and evaluated with at least 6 months follow-up (mean 2.6 years). Sonography or mammography, clinical examination, patient questionnaire (10-point Likert scale) and digital photographs were carried out."

**Results:** "On average the patients received 4 to 6 procedures each with a single volume of 159 ml ( $\pm 61$  ml) over 21 months (range 9 months to 2.5 years). In total 1,020ml ( $\pm 515$ ml) fat were grafted till a complete breast reconstruction was achieved. Irradiated patients needed a significantly higher volume than non-irradiated ( $p < 0.041$ )."

"A complete breast reconstruction with large volume fat grafting is alternatively possible to standard techniques in selected cases. It takes at least 4 to 6 lipotransfers in the course of 2 years. Patients with prior radiotherapy may require even up to 8 sessions over nearly 3 years of treatment."

**Conclusion:** "Our study demonstrates that autologous fat grafting is a suitable way not only to restore local defects after conservative breast reconstructive surgery or radiodamages, but also to achieve complete breast reconstruction."

In irradiated patients, "pretreatment with 4 ambulant small volume graftings of 50-80 ml fat to resolve scar fibrosis" gradually "decreased chronic tissue injury and an adequate recipient area can be obtained."

"The grafting technique is easy combinable with other oncoplastic methods like NAC reconstruction or contra lateral mastopasty."

## 10. WAL fat grafting with and without stem cell enrichment

H. Peltoniemi, A. Salmi, S. Miettinen et al.: Stem cell enrichment does not warrant a higher graft survival in lipofilling of the breast: A prospective comparative study. Journal of Plastic, Reconstructive & Aesthetic Surgery (2013) 66, 1494e1503.

The prospective comparative study evaluates a "total of 18 women who underwent breast augmentation with water-assisted lipotransfer (WAL)." "Liposuction for retrieval of fat was performed according to the WAL method, as described before, under local anaesthesia and light sedation. The body-jet system was used in combination with the LipoCollector (Human Med AG, Schwerin, Germany)."

"In 10 of the cases, transferred lipoaspirate was enriched with stromal stem cells using the Celution system (Cytosol Therapeutics Inc., San Diego, Ca, USA). Magnetic resonance imaging (MRI)-based volumetric analysis was done preoperatively and 6 months after the procedure. To verify scientifically that stem cells were transplanted, samples of the transplanted tissues were processed in the laboratory to isolate the adipose stem cells (ASCs).

**Results:** "MRI volumetry revealed a volume survival of the whole (watery) graft of mean 54% (SD 7) in the WAL only and of 50% (SD 10) in the WAL with stem cell-enrichment patients.

As centrifugation of the WAL grafts demonstrated an average adipose tissue of 68%, the average volume survival of adipose tissue itself was 79% (SD 13) in the WAL only and 74% (SD 14) in the WAL with stem cell-enrichment patients. This difference (4.5%) was not statistically significant (independent samples t test,  $p > 0.330$ , 95% confidence interval of difference, 4.8, 13.9%)."

"Breast augmentation by lipofilling using WAL alone is faster, cheaper, has a lower risk of contamination and offers at least an equal take rate. We do not see any advantage in stem cell enrichment by the Celution system in cosmetic fat transplantation to the breast."

**Conclusion:** "We found a high survival rate after WAL and cell enrichment in the presented patients, but not better than in patients purely treated with WAL, without stem cell enrichment. WAL alone is faster (90-150 min less), cheaper (cost of consumables for Celution was over 3000 euros for each patient), theoretically safer (lower risk of contamination) and offers at least the same take rate. We do not see any advantage in stem cell enrichment by the Celution system in cosmetic fat transplantation to the breast. The indications for CAL are rather to be seen in regenerative medicine."

## 11. WAL breast augmentation & reconstruction

T. K. Malan: Breast Augmentation and Reconstruction with Fat Transfer. In: Cosmetic Surgery - Art and Techniques; Shiffman, Melvin A., Di Giuseppe, Alberto (Eds.), 2013, pp 595-603

In this educational book on breast augmentation and reconstruction, the author explains his operative technique as follows:

"Following marking the fat is removed from the donor site with the Body-Jet system with LipoCollector to harvest the fat under low pressure (12 in. Hg). Smooth, slow, even passes of harvesting cannula with care taken to not torque the tissue or to rapidly vent cannula causing splash injury as fat rushes into collector. The LipoCollector® drains excess tumescent solution utilizing a 300-micron filter leaving minimally processed fat."

## 12. WAL for reconstructive and aesthetic breast augmentation

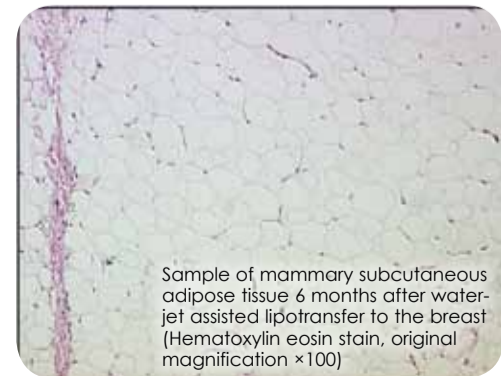M. Stabile, K. Ueberreiter, H. E. Schaller, D.L.Hoppe: Jet-assisted fat transfer to the female breast: preliminary experiences. European Journal of Plastic Surgery March 2014

"After the first report in 2010, the Berlin Autologous Lipotransfer (BEAULI) method became one of the latest popular techniques in the field of large volume fat grafting. Preliminary experiences with the rising jet-assisted fat transfer in a large case series of two specialized European centers are presented."

"Retrospective analysis enrolled over 167 female nonsmokers with reconstructive or aesthetic indications treated with at least one procedure according to the standardized protocol of the BEAULI™ technique from February 2010 to June 2012. The fat's harvest is carried out in a sterile closed system with a low suction force, avoiding overly mechanical trauma or thermal damage [38]. The WAL system uses nearly 70% less tumescent fluid than other liposuction systems [39]. In this way, local swelling and bloating are minimized, preserving the contours of the target area. With the LipoCollector™ system, neither centrifugation nor additional washing are required."

**Results:** "The study included 132 patients (240 breasts) had a mean age of 39.7 years and underwent 487 autologous jet-assisted fat transfer procedures with minor complications (5.35%) like tiny oil cysts formations or hematoma of the donor site. Low postoperative pain (88.6% with VAS 1 to 4) has been reported during the first week, and final aesthetic evaluation showed good to excellent results. We observed a higher frequency of procedures, especially in irradiated patients ( $>3.62$ ) compared to the rest of reconstructive cases ( $>2.78$ )."

**Conclusions:** "Water-jet-assisted liposuction with consecutive immediate mammary fat injection is a procedure with a short hospitalization and low complication rate. Based on the preliminary results in the use of the BEAULI™ technique for breast reconstruction and aesthetic augmentation, the authors presume that it can be safely applied for these specific patient groups."



Sample of mammary subcutaneous adipose tissue 6 months after water-jet assisted lipotransfer to the breast (Hematoxylin eosin stain, original magnification  $\times 100$ )